

# Endodontics

## Lecture 3

Dr.Jaber AL Ibraheem

### Endodontic Radiography

The dental radiograph allows indirect vision to the dentition and supporting structures, and provides standardization of intracanal procedures. As a result, radiographs are a very important aid for endodontic diagnosis and treatment.

#### **Basic radiographic concepts**

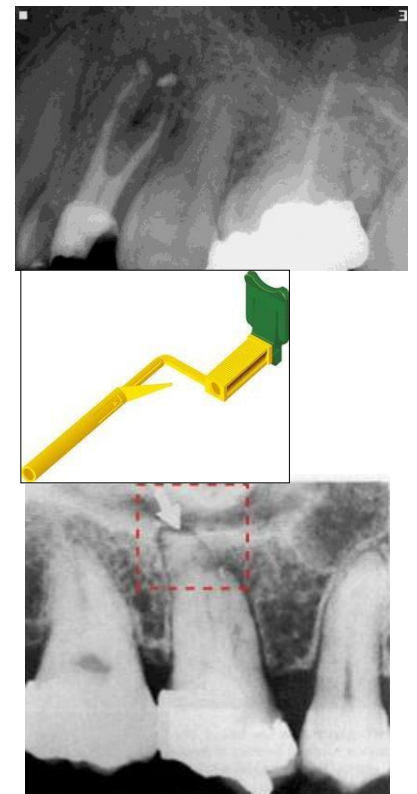
- 1- X-rays are similar to light rays in that both travel in a straight line until deflected or absorbed. Deflected rays reduce image clarity.
- 2- The radiograph is a shadow image representing differences in a density of objects in the x-rays path. Therefore, the radiograph is a two dimensional image of a three dimensional structure.
- 3- The size, shape and contrast of the shadow image are subjected to many distortions since they are dependant on the physical properties of:
  - a) The object through which the x-ray passes.
  - b) The radiation source.
  - c) The film on which the image is recorded.

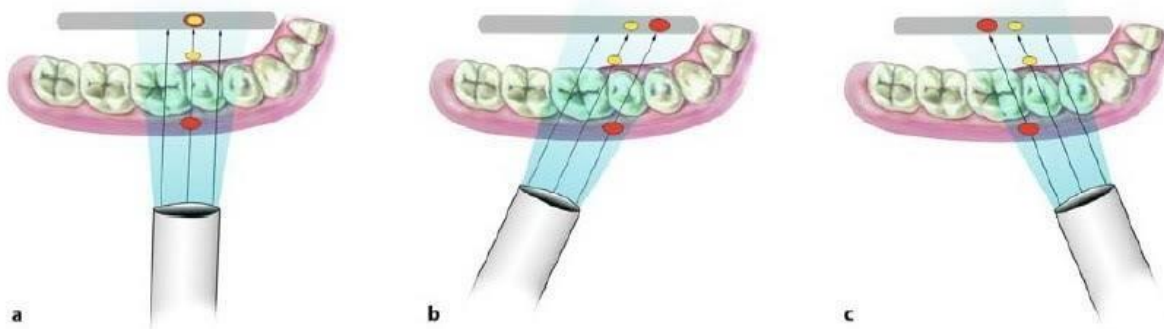
#### **Suggestions for good endodontic radiography**

- 1- For periapical exposures the edge of the film is positioned parallel to and near the incisal or occlusal surface of the teeth so that the tooth apices are near the center of the film.
- 2- The plastic film holder facilitates standardization of a radiographic technique by aiding in film positioning and preventing movement of the film during exposure.
- 3- Because of the angle of the hard palate the films that are held by the finger usually show maxillary molars with short buccal roots and very long palatal root.

#### **Buccal object rule**

When treating premolars and molars, it is often difficult to recognize radiographically which canal is nearer buccal side. When the exposure is done to a multicaaned tooth, the canals may be superimposed and the difficult to differentiate them. If the x-ray cone is deviated mesially or distally with a given angle the roots will separate in the film. Therefore, when the cone is moved distally the buccal canal appears mesial to the lingual or palatal canal and when the cone is moved mesially the buccal canal appears distal to the lingual or palatal canal. .





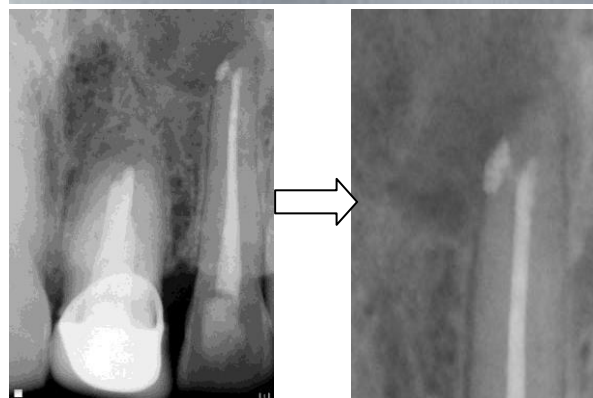### Factors that affect the quality of the radiograph and its interpretation.

1- Radiolucent rubber dam frames do not interfere with taking radiography. Metal frames may mask important structures on the film.

2- A quick automated processing technique offers a clear radiograph. It maintains a water bath heated by a thermostatically controlled heater that maintains the developer and fixer at 100 F, so shortening the time needed to process a radiographic film. The exposed film is immersed in the developer for 5-10 seconds, rinsed with water and then placed in the fixer until it becomes clear (15-20 seconds).

3- All endodontic radiographs must be dated and mounted in chronological sequence to allow for immediate reference.

4- Film magnification is essential to see clearly detailed structures in the film and this is done a magnifying lens. Nowadays, there is no need for this lens because digital radiography allows detailed picture that can be zoomed in clearly.



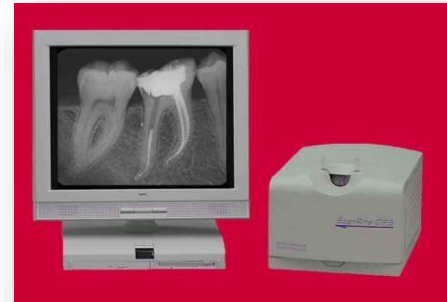### Information gained from the radiograph

- 1- The crown and pulp anatomy
- 2- Hard tissue alterations in the tooth (sclerosis or resorption)
- 3- Number, size, location and direction of the roots
- 4- Estimation of the working length
- 5- Related anatomical structures as mental foramen, maxillary sinus etc...
- 6- Confirm position of master cone
- 7- Evaluation of success of obturation
- 8- Instrument separations or perforations.

## **Digital radiography:**

As dentistry moves to more precise quality so does diagnosis therefore it was important to change the traditional xray films to a more precise film and here digital radiography entered the diagnostic field. Digital radiography used in dentistry is available in three variations:

- 1) Direct digital system: It uses a solid-state sensor such as a charge coupled device (CCD). These systems have a cable that connects the sensor to the computer and in turn to screen monitor.
- 2) Storage phosphor system: It uses a photo-stimulable phosphor plate that stores the image in the phosphor for subsequent readout by an extra-oral laser scanner.
- 3) Indirect digital system: It uses a scanning device connected to a computer for digitizing traditional silver halide dental films.



### **Advantage of digital radiography:**

- 1) Image enhancement, contrast stretching and reversing.
- 2) Storage for further use and evaluation.
- 3) Retrieval immediately.
- 4) Transmission of images to remote sites in a digital format.
- 5) Radiation exposure is reduced from 50% to 90% compared with conventional film-based radiography.

### **Disadvantages:**

- 1) High initial cost.
- 2) Reduction in image quality when compared with conventional radiography.

### **Direct digital systems have three components:**

- 1) Radio component: It consists of a high resolution sensor with an active area that is similar in size to conventional film. For infection control, disposable plastic sheaths are used to cover the sensor when it's in use.
- 2) Visio component: It consists of a video monitor and display-processing unit. As the image is transmitted to the processing unit, it's digitized and stored by the computer.
- 3) Printing component: High resolution printer providing a hard copy of the screen image.

